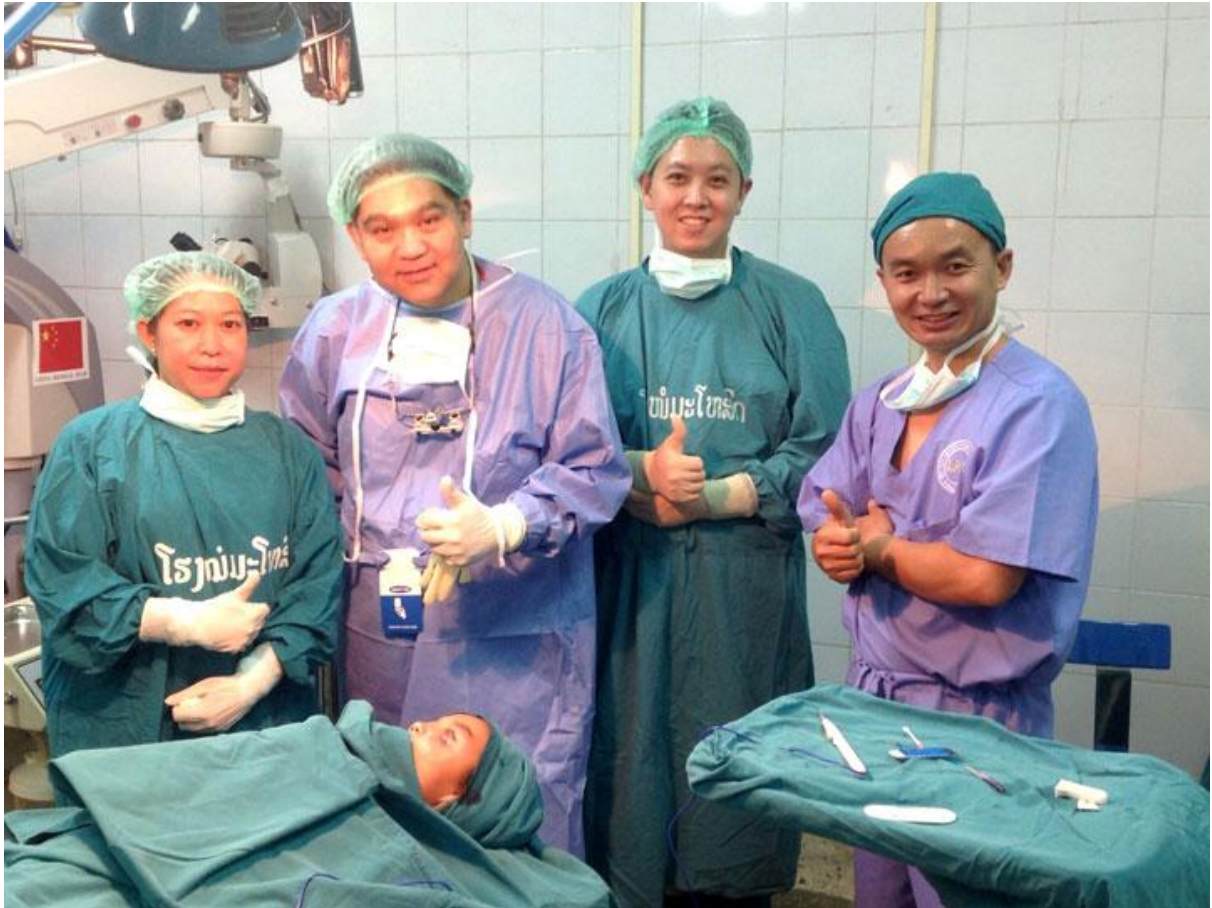

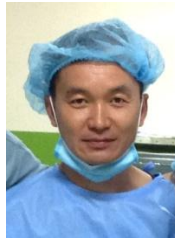ATTACHMENT 1: TEAMWORK



CATARACT SURGERY TEAM

Oudomxay Team

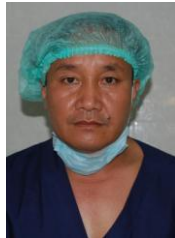1. Phetsamone Indara, M.D.
*Ophthalmologist,
Head of Eye Unit
Oudomxay Provincial Hospital
Tel: (856-20)2220 3708
Email: inda_oph@yahoo.com*



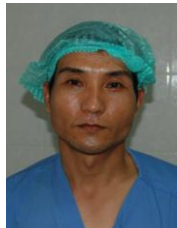
2. SengLa Laoern, MD
*Ophthalmologist
Oudomxay Provincial Hospital
Tel: (856-20) 2254 1222
Email: sla_chen_23@yahoo.com*



3. Phonthavy Inthavongsa
*Ophthalmic nurse
Tel: (856-20) 2284 1751*



4. Khamtan Phanthou Amath
*Ophthalmic nurse, optometrist
Tel: (856-20) 5651 9349*



5. Souliyo Setsongkham
*Ophthalmic nurse
Tel: (856-20) 5658 6501*



6. Sipha Khounmala
*Ophthalmic nurse
Tel: (856-30) 5128752*



Xayabury Team

1. Somchit, M.D.
*Ophthalmologist,
Head of Eye Unit
Xayabury Provincial Hospital
Tel: (856-20) 5566 9670
Email: somchit54@yahoo.com*



2. Pathoumphone, M.D.
*Residency Ophthalmology,
Xayabury Provincial Hospital
Tel: (856-20) 2248 4748*



3. Mrs. Bouaphan Chanda
*Ophthalmic nurse
Xayabury Provincial Hospital
Tel: (856-20) 5589 6298*



4. Mrs. Khamphone Khammavong
*Ophthalmic nurse
Xayabury Provincial Hospital
Tel: (856-20) 5517 4145*



Thai Team

Nattawut Wanumkarng, MD

Oculoplastic Surgeon

*Director of Oculoplastic Fellowship Program,
Bumrungrad International Hospital and At Eye Clinic*

Email: wanumkarng@gmail.com



Nathaphon Apimeteetamrong, MD

Oculoplastic Fellow

Bumrungrad International Hospital and At Eye Clinic

Email: nathaphonapi@gmail.com



LRF Team

Sasithone Sengchanh

Coordinator LRF

Tel (856-20) 54455944

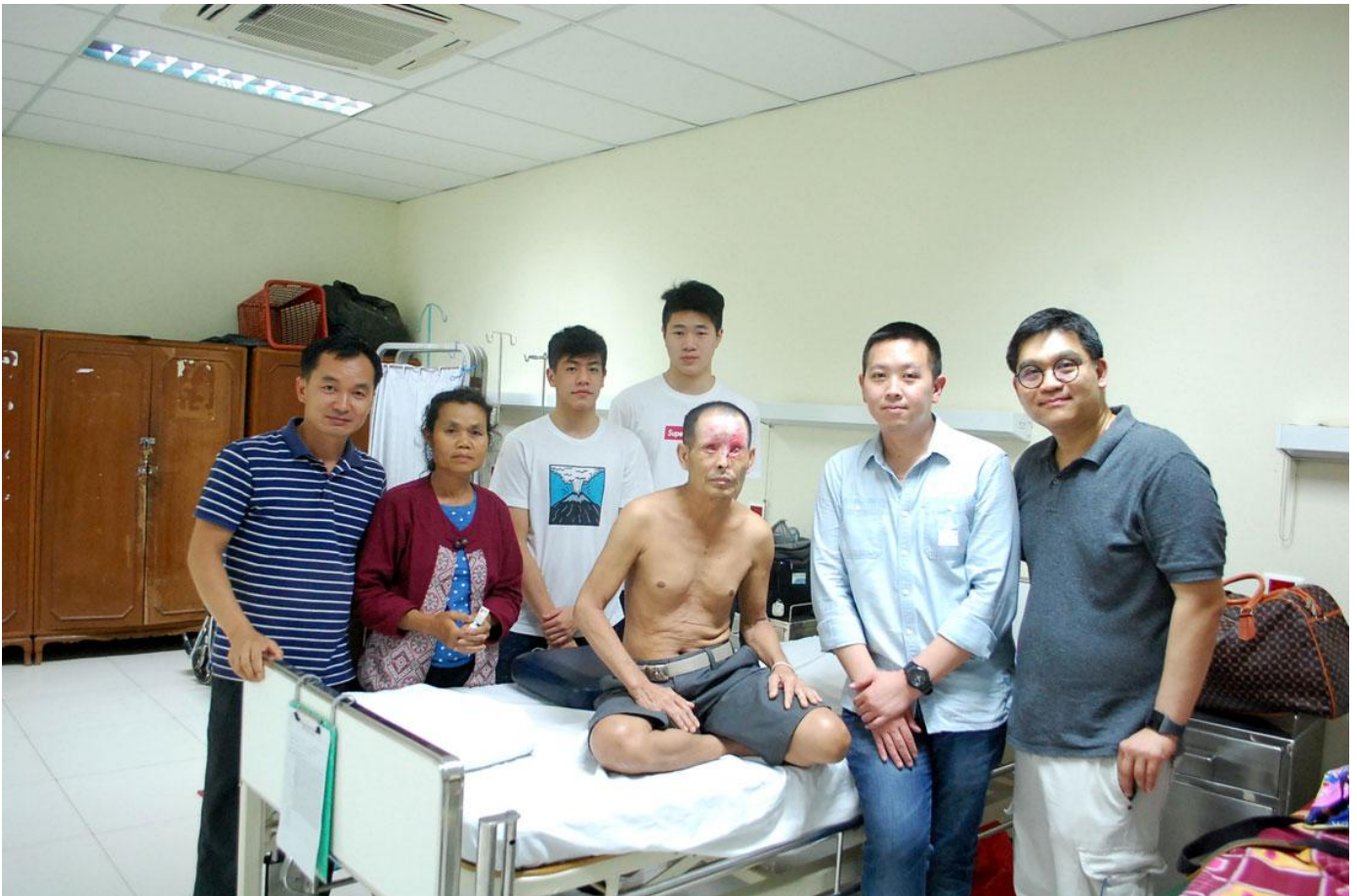Email: sasithone2s@yahoo.com



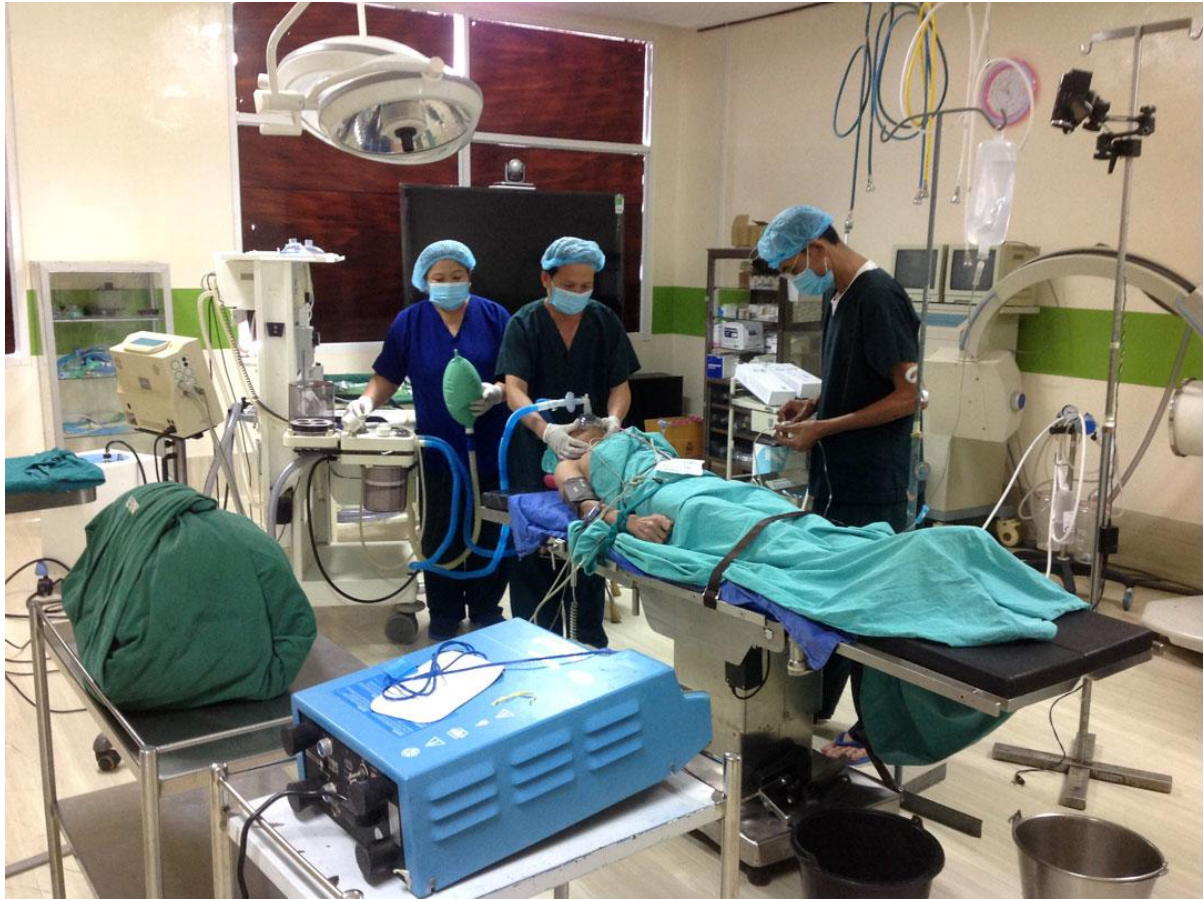ATTACHMENT 2: PHOTO OF ACTIVITIES



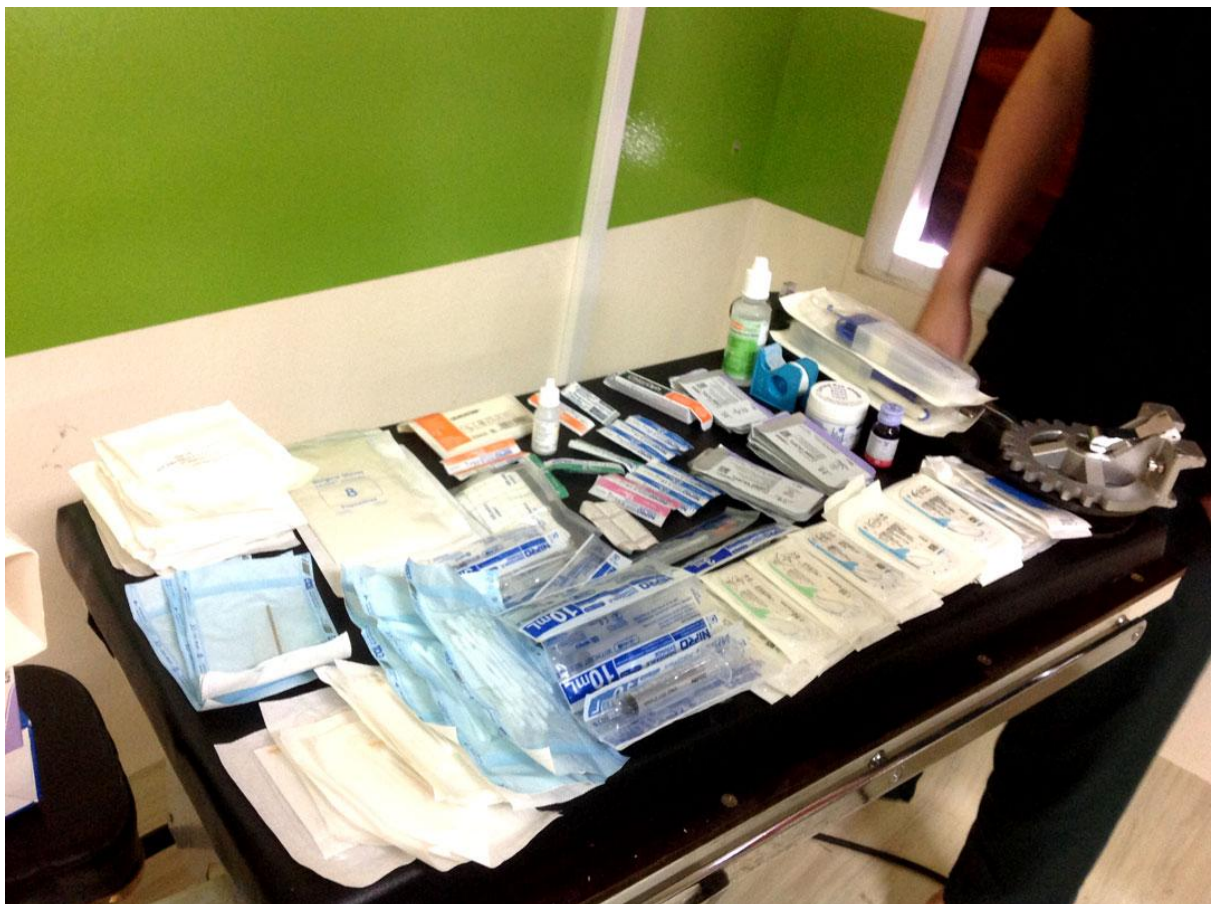A little girl and burned man are examined before surgery *By Dr. Nattawut and team*



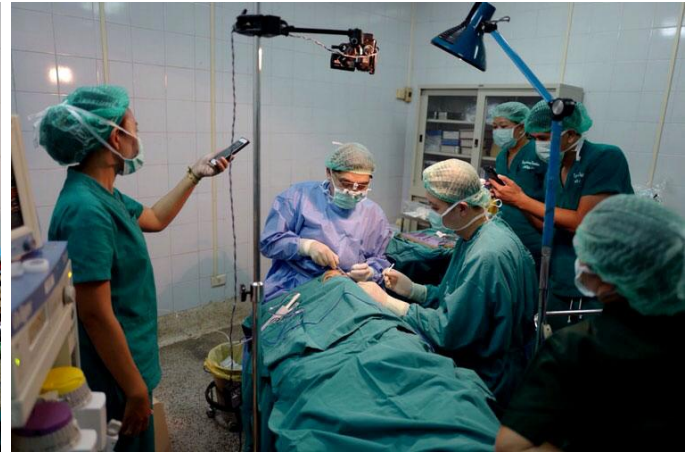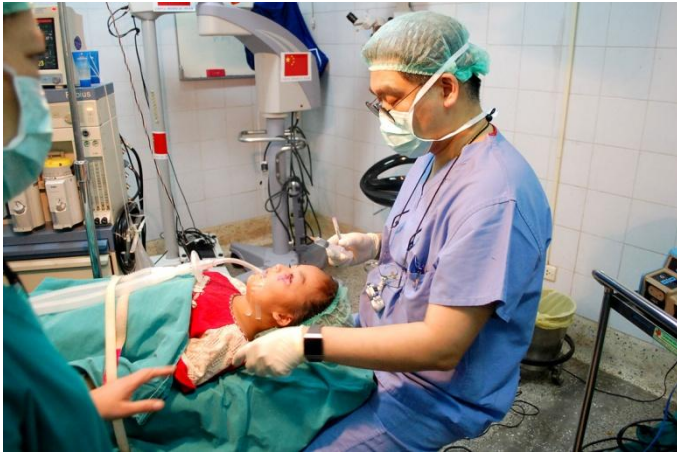A man with eyelid lost by burn, his wife and team before surgery



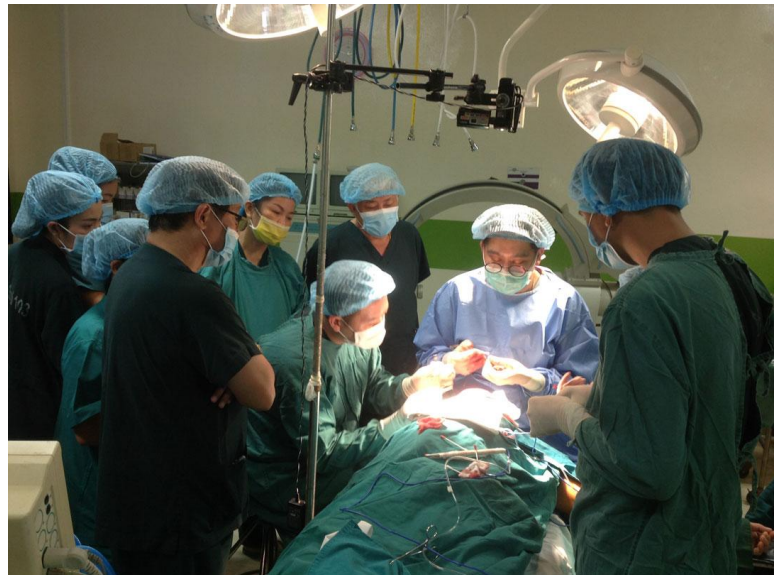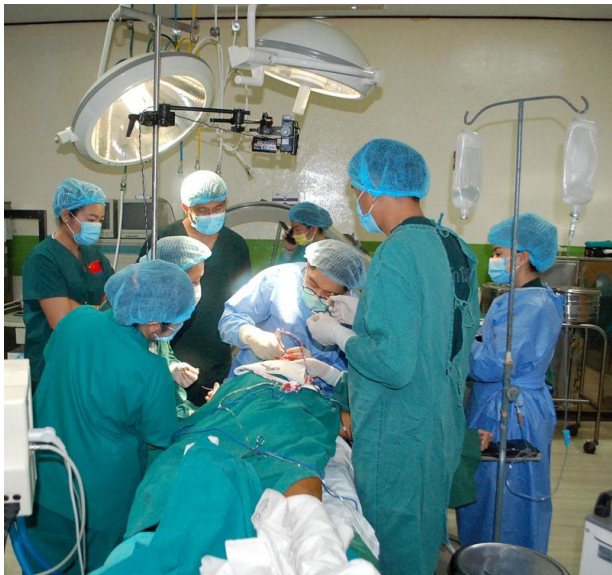Anesthesia team
are setting up patient pre-surgery



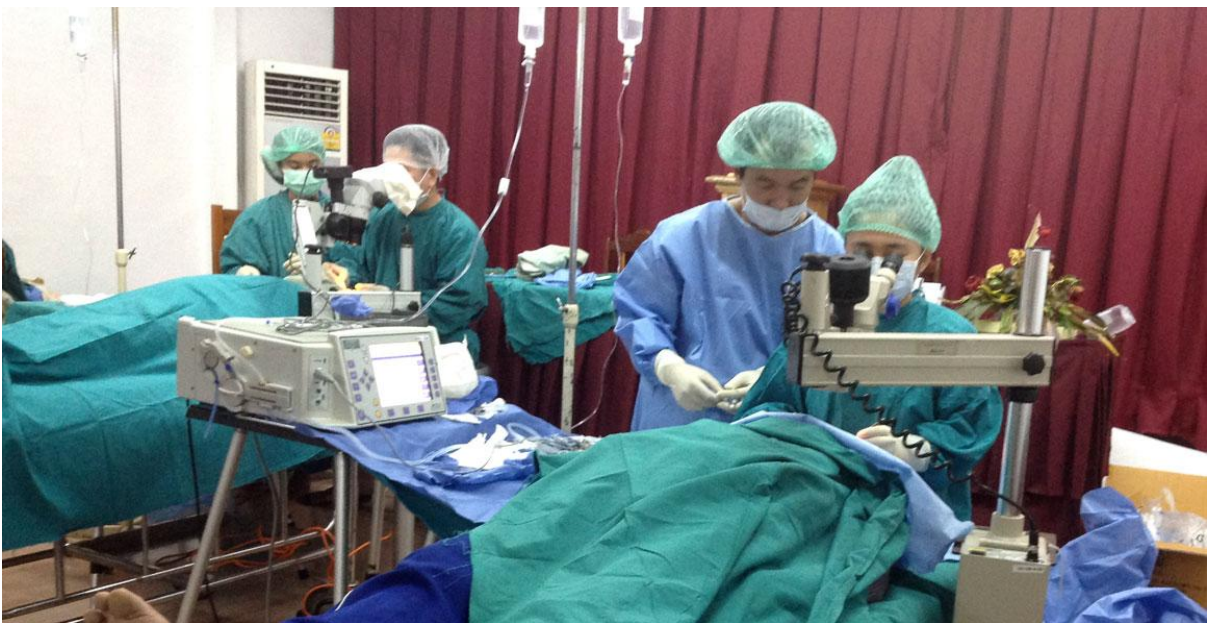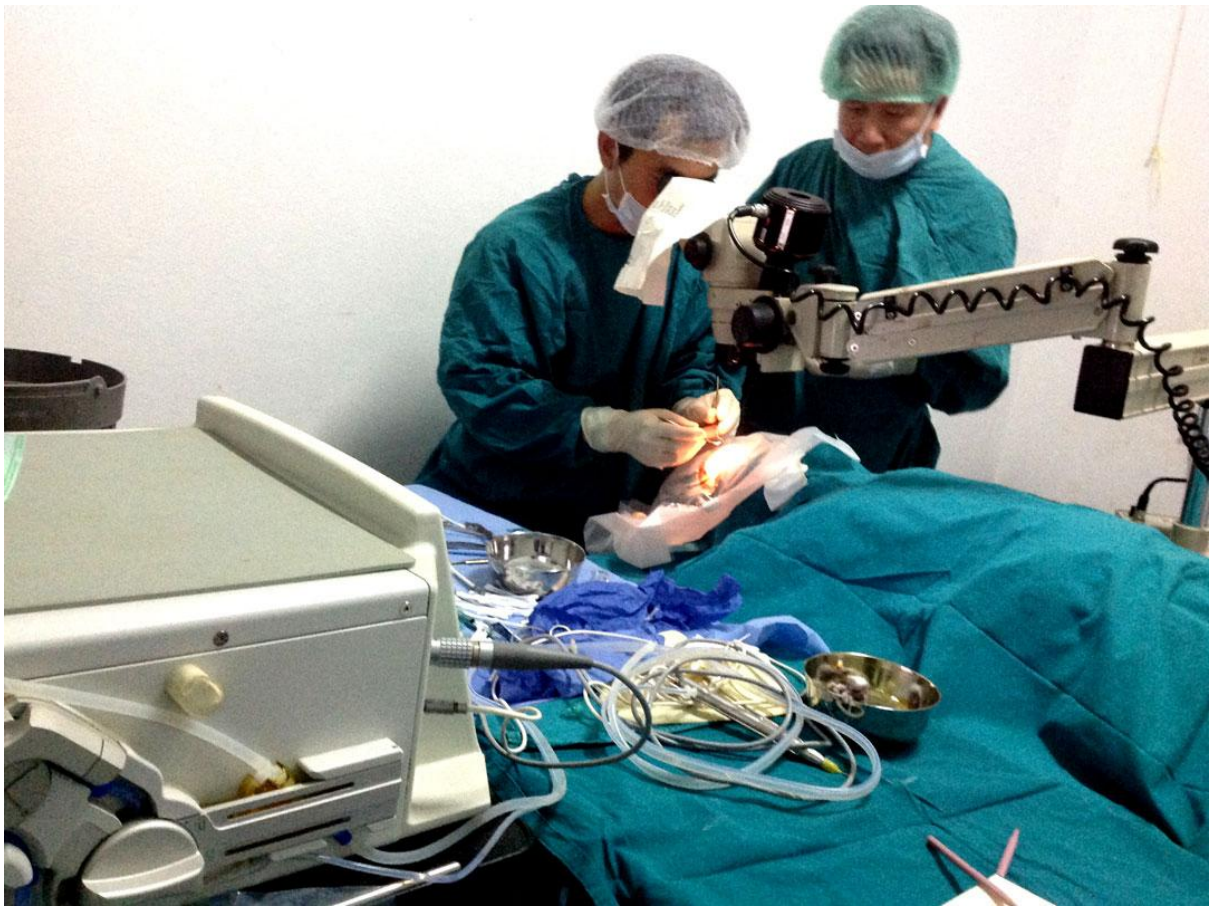Medicine and supplies for surgery



A little girl with lower lid retraction and ectropion repaired by Z-plasty technique
By: Dr. Nattawut and team



A man with severe burn eyelid loss repaired with full thickness skin graff and Tarsorrhaphy
By: Dr. Nattawut and team



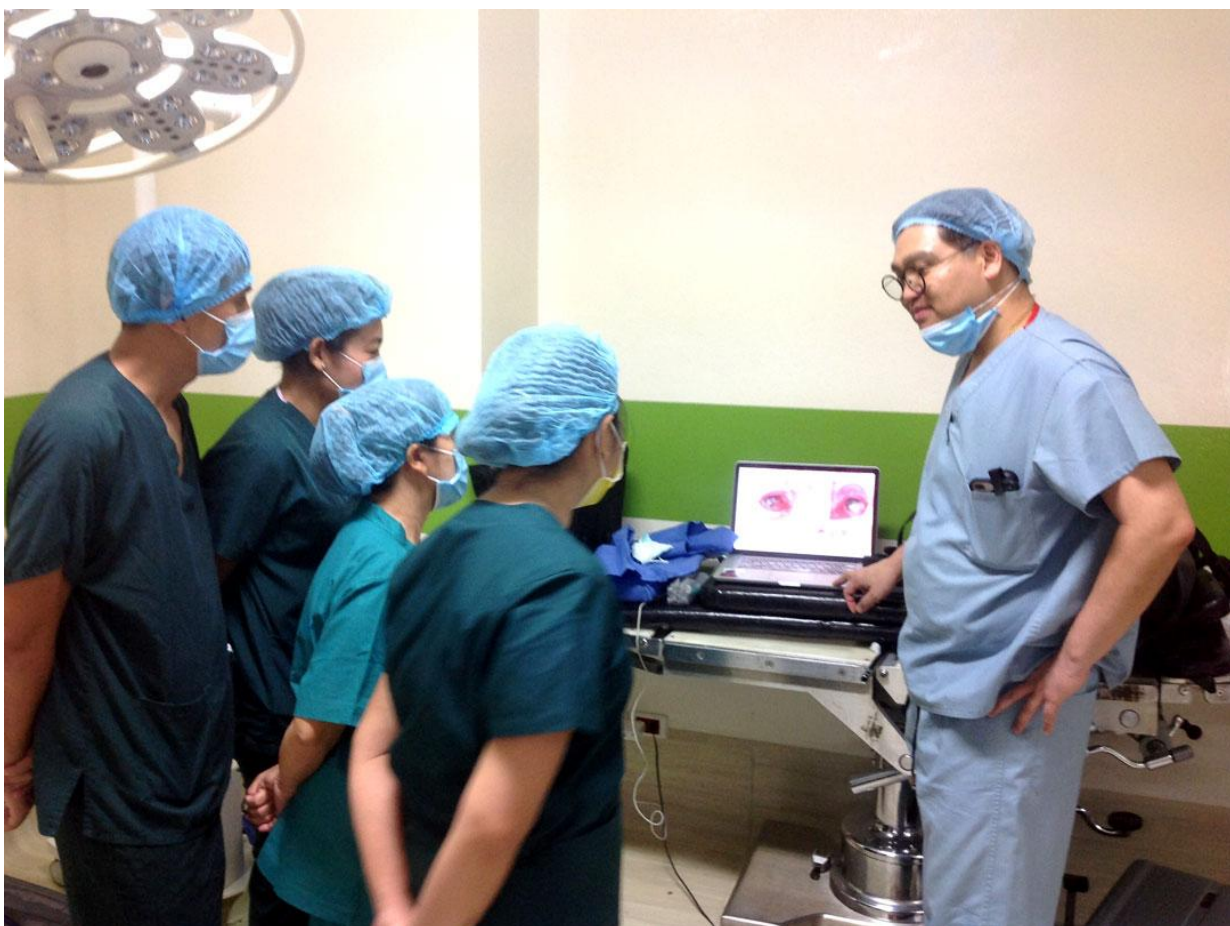Cataract Surgery using Phacoemulsification and MSICS techniques
By: Dr. Phetsamone and team



Cataract post-surgery 1st day



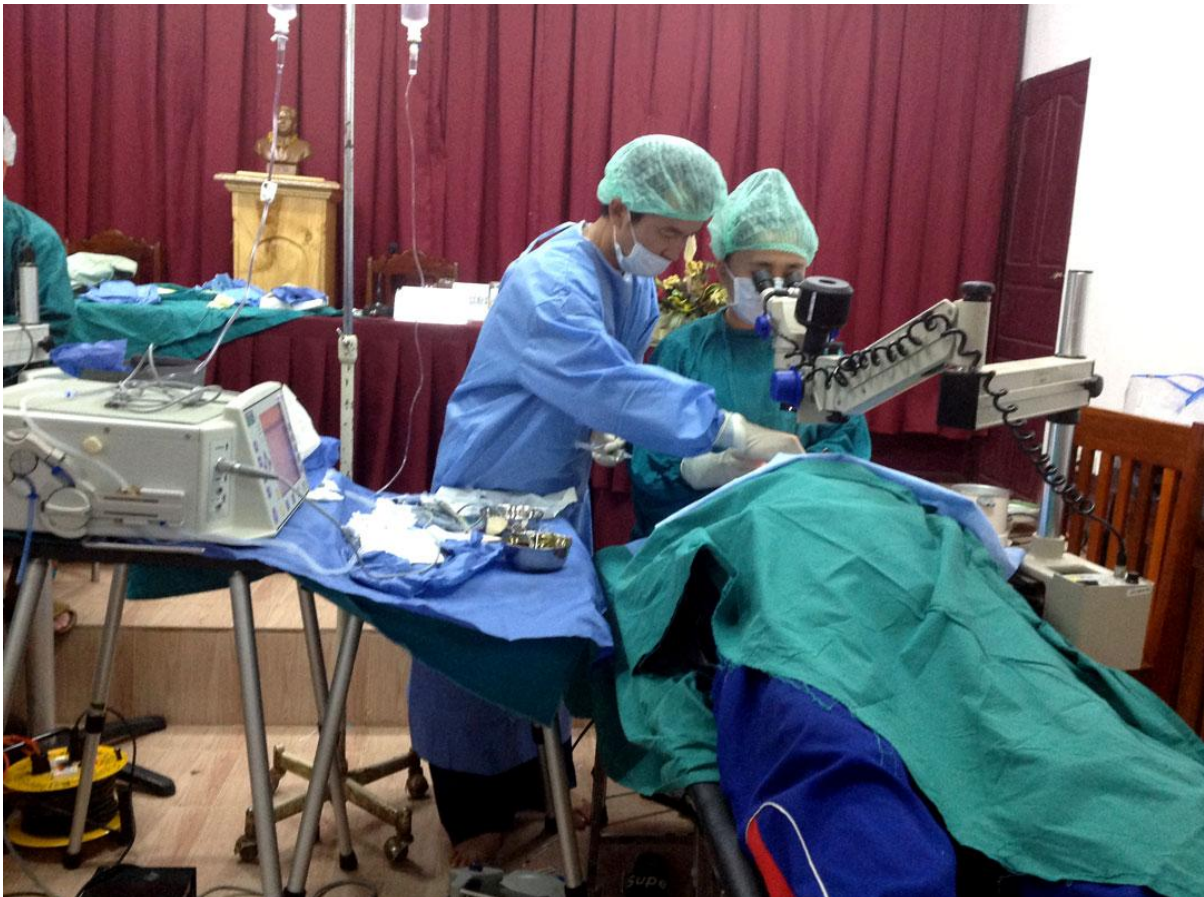Dr. Nattawut is teaching Dr. Phetsamone
How to repair eyelid by Z-plasty technique



Dr. Nattawut is teaching Lao ophthalmologists
About case with severe eyelid loss



Dr. Phetsamone is teaching Xayabury ophthalmologists *how to use and maintain AB-scan*



Dr. Phetsamone is teaching residency ophthalmologists *how to perform MSIC surgery*

ATTACHMENT 3: PHOTO OF PATIENT BEFORE AND POST SURGERY

Name	Before Surgery	Post-Surgery
<p>A man 60 years old</p> <p>Severe burn with eyelid loss BE PH: Fire burned in November 2017.</p> <p><u>Surgery technique:</u> Eyelid repair with full thickness skin graft and Tarsorrhaphy</p>		
<p>A little girl 7 years old</p> <p>Lowerlid retraction and ectropion PH: Severe ectropion and retraction on left lower eyelid secondary to the severe infection of left maxillary sinus with chronic cutaneous fistula.</p> <p><u>Surgery technique:</u> Repaired eyelid by Z-plasty technique</p>	 	