

ATTACHMENT 1: Photo of Activities

Registration

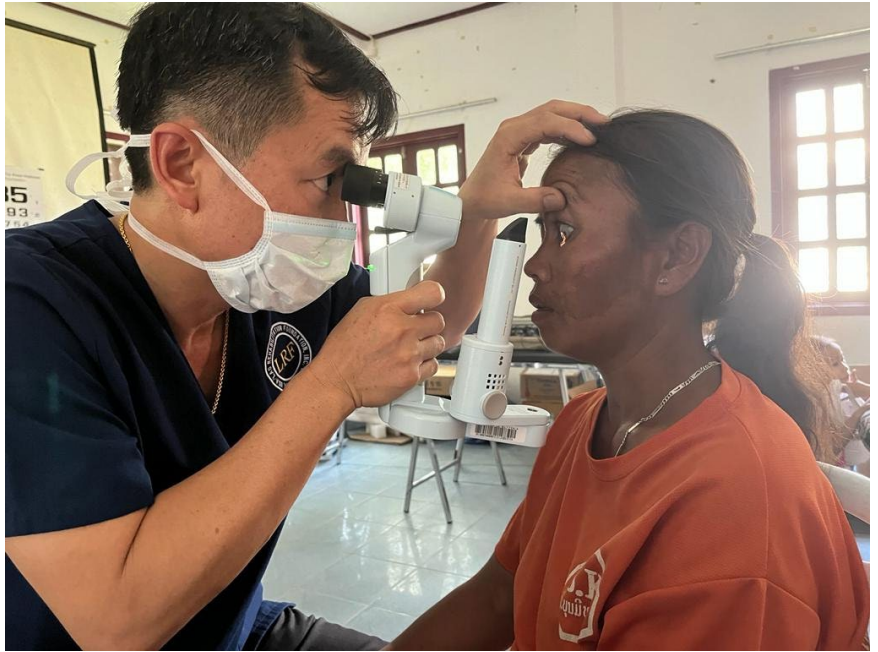
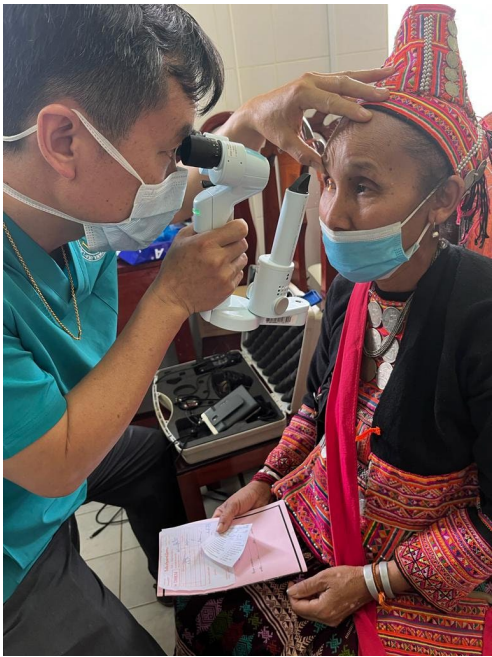
Eye patients registering and waiting to be examined, many ethnic groups at Mai district hospital

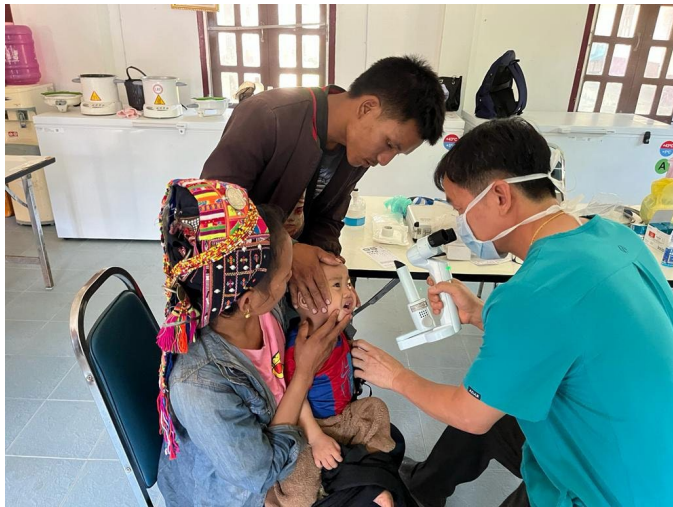

Dr. Luc and 2 young brothers with bilateral congenital cataract and their parents at Mai district hospital

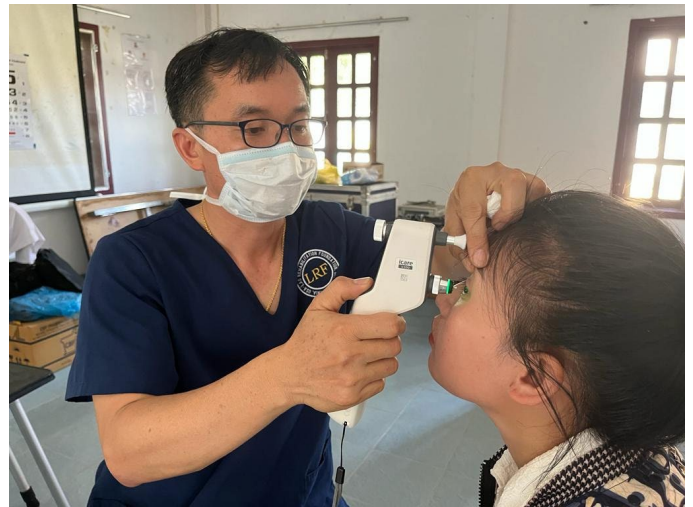Eye Examination, Diagnosis with Medical Treatment



**Eye examined with mobile slit lamp
by Dr. Phetsamone**

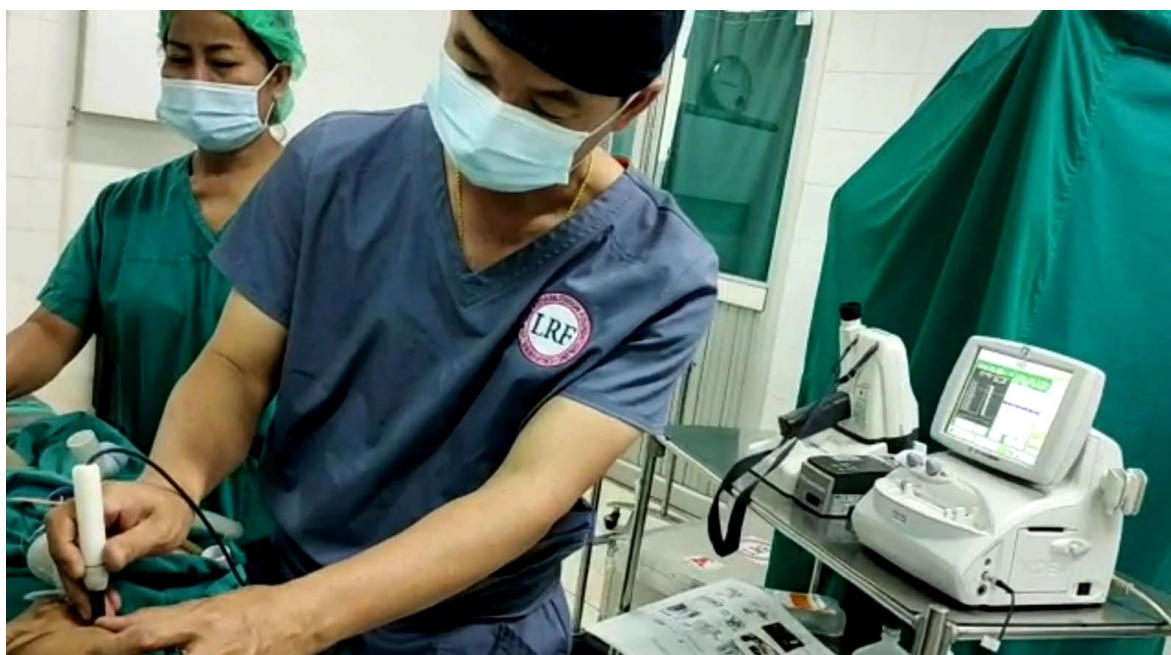

**A boy with congenital cataract examined
with mobile slit lamp
by Dr. Phetsamone**

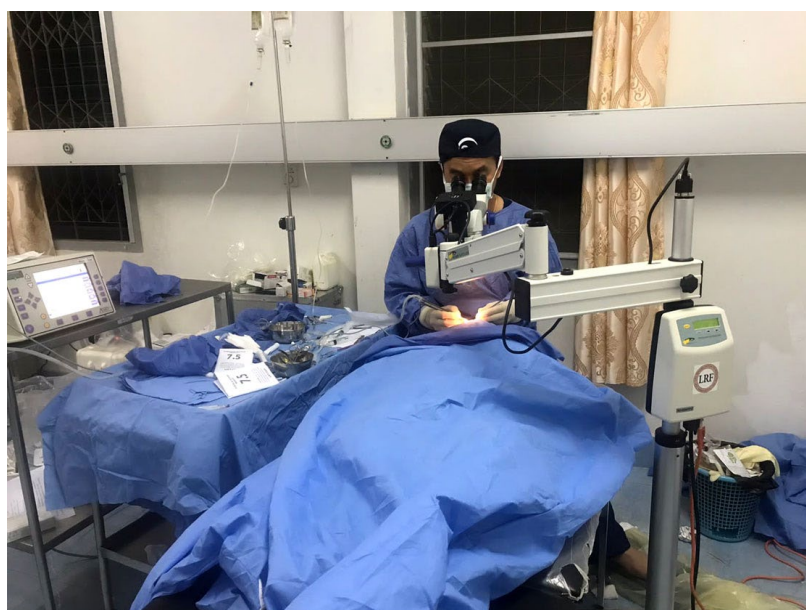


**Patient is tested for Intraocular pressure (IOP)
with iCare Tonometer
by Dr. Phetsamone**

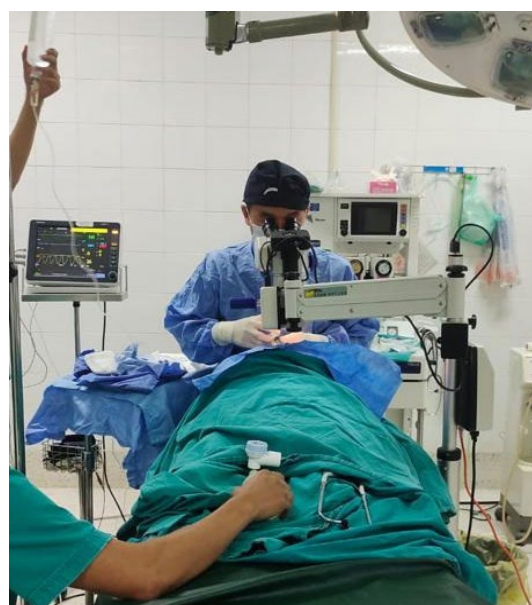Cataract Surgery with IOL Implant



Intraocular lens (IOL) power calculation with Renito-max and A-Scan for a boy with congenital cataract
by Dr. Phetsamone and Anesthesia team

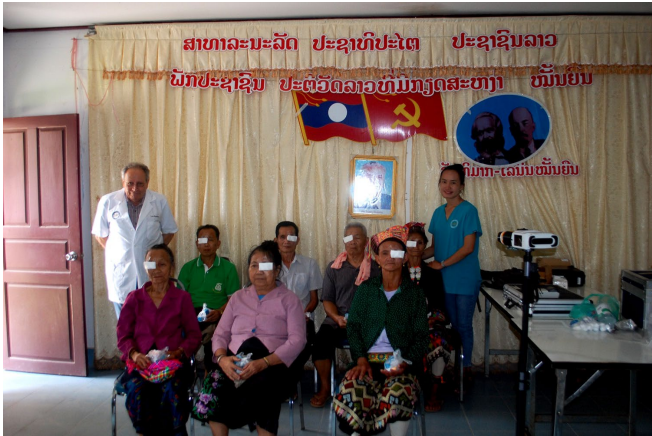

Cataract surgery using Phacoemulsification technique.
At Khoua district hospital
by Dr. Phetsamone

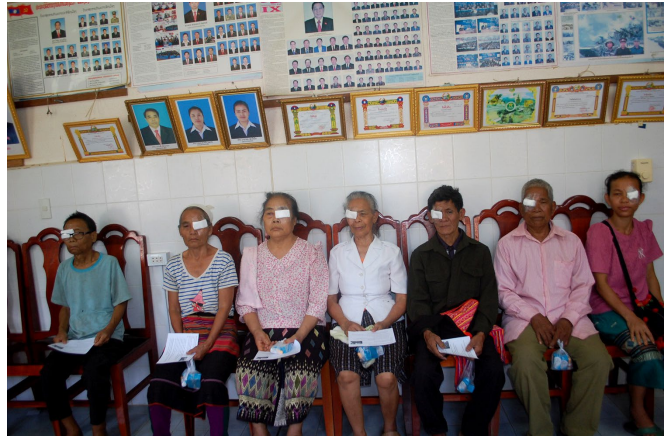

Congenital Cataract surgery
At Oudomxay Provincial Hospital
by Dr. Phetsamone and anesthesia team

Cataract Post-operative (1)



Dr. Luc, Ms. Khaman and patients post surgery on the 1s day at Mai District Hospital

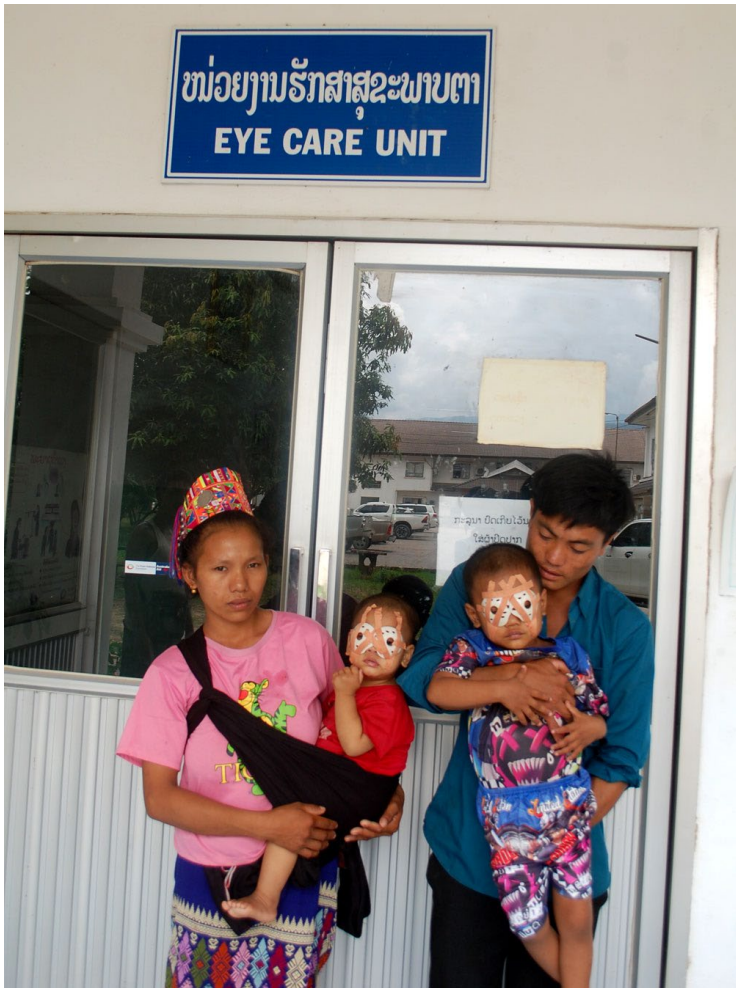

Patients post surgery on the 1s day at Khoua District Hospital

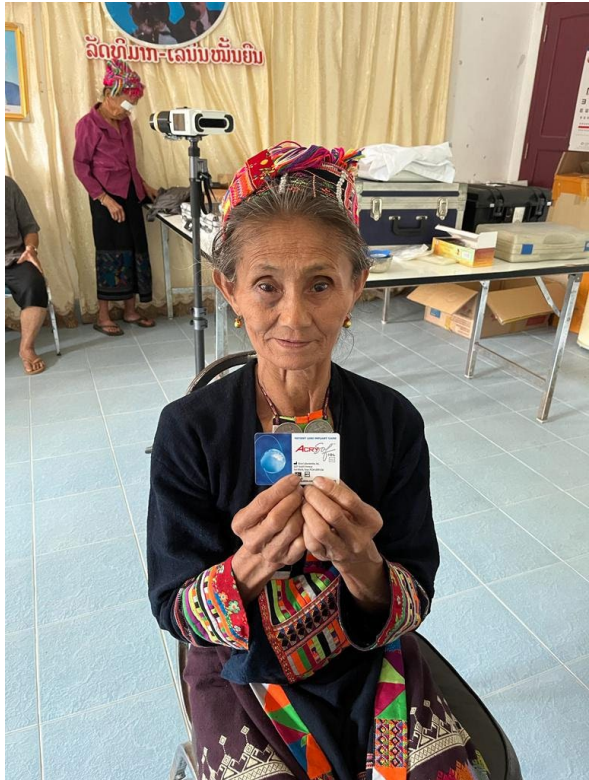

Patients post surgery on the 1s day at Oudomxay Provincial Hospital

Cataract Post-operative (2)



2 boys with congenital cataract and parents post surgery on 1st day



An old ethnic minority patient shows her IOL Card post surgery on 1st day

Refractive Service and Provide Glasses



**Patient is checked for refraction with QuickSee autorefractor
by Ms. Khamman, optometrist**



**Patient is checked for refraction and received new glasses
by Ms. Khamman and Dr. Luc**